

# Resident Manual of Trauma to the Face, Head, and Neck

First Edition



AMERICAN ACADEMY OF  
OTOLARYNGOLOGY-  
HEAD AND NECK SURGERY

F O U N D A T I O N

©2012 All materials in this eBook are copyrighted by the American Academy of Otolaryngology—Head and Neck Surgery Foundation, 1650 Diagonal Road, Alexandria, VA 22314-2857, and are strictly prohibited to be used for any purpose without prior express written authorizations from the American Academy of Otolaryngology—Head and Neck Surgery Foundation. All rights reserved.

For more information, visit our website at [www.entnet.org](http://www.entnet.org).

eBook Format: First Edition 2012.

ISBN: 978-0-615-64912-2

## Preface

The surgical care of trauma to the face, head, and neck that is an integral part of the modern practice of otolaryngology–head and neck surgery has its origins in the early formation of the specialty over 100 years ago. Initially a combined specialty of eye, ear, nose, and throat (EENT), these early practitioners began to understand the inter-relationships between neurological, osseous, and vascular pathology due to traumatic injuries. It also was very helpful to be able to treat eye as well as facial and neck trauma at that time.

Over the past century technological advances have revolutionized the diagnosis and treatment of trauma to the face, head, and neck—angiography, operating microscope, sophisticated bone drills, endoscopy, safer anesthesia, engineered instrumentation, and reconstructive materials, to name a few. As a resident physician in this specialty, you are aided in the care of trauma patients by these advances, for which we owe a great deal to our colleagues who have preceded us. Additionally, it has only been in the last 30–40 years that the separation of ophthalmology and otolaryngology has become complete, although there remains a strong tradition of clinical collegiality.

As with other surgical disciplines, significant advances in facial, head, and neck trauma care have occurred as a result of military conflict, where large numbers of combat-wounded patients require ingenuity, inspiration, and clinical experimentation to devise better ways to repair and reconstruct severe wounds. In good part, many of these same advances can be applied to the treatment of other, more civilian pathologies, including the conduct of head and neck oncologic surgery, facial plastic and reconstructive surgery, and otologic surgery. We are indebted to a great many otolaryngologists, such as Dr. John Conley's skills from World War II, who brought such surgical advances from previous wars back to our discipline to better care for patients in the civilian population. Many of the authors of this manual have served in Iraq and/or Afghanistan in a combat surgeon role, and their experiences are being passed on to you.

So why develop a manual for resident physicians on the urgent and emergent care of traumatic injuries to the face, head, and neck? Usually the first responders to an academic medical center emergency department for evaluation of trauma patients with face, head, and neck injuries will be the otolaryngology–head and neck surgery residents. Because there is often a need for urgent evaluation and treatment—bleeding and

airway obstruction—there is often little time for the resident to peruse a reference or comprehensive textbook on such trauma. Thus, a simple, concise, and easily accessible source of diagnostic and therapeutic guidelines for the examining/treating resident was felt to be an important tool, both educationally and clinically.

This reference guide for residents was developed by a task force of the American Academy of Otolaryngology—Head and Neck Surgery (AAO-HNS) Committee on Trauma. AAO-HNS recently established this standing committee to support the continued tradition of otolaryngology-head and neck surgery in the care of trauma patients. An electronic, Portable Document Format (PDF), suitable for downloading to a smart phone, was chosen for this manual to facilitate its practical use by the resident physician in the emergency department and preoperative area.

It should be used as a quick-reference tool in the evaluation of a trauma patient and in the planning of the surgical repair and/or reconstruction. This manual supplements, but does not replace, more comprehensive bodies of literature in the field. Use this manual well and often in the care of your patients.

**G. Richard Holt, MD, MSE, MPH, MABE**

*Editor and Chair*

*Task Force on Resident Trauma Manual*

**Joseph A. Brennan, MD, Colonel, MC, USAF**

*Chair*

*AAO-HNS Committee on Trauma*

## Acknowledgments

This quick reference guide for resident physicians in trauma management reflects the efforts of many individuals in the American Academy of Otolaryngology—Head and Neck Surgery and a special task force of the AAO-HNS Committee on Trauma.

The editors would like to thank all of the authors who generously gave their time and expertise to compose excellent chapters for this Resident Manual in the face of busy clinical and academic responsibilities and under a very narrow timeframe of production. These authors, experts in the care of patients who have sustained trauma to the face, head, and neck, have produced practical chapters that will guide resident physicians in their assessment and management of such trauma. The authors have a wide range of clinical expertise in trauma management, gained through community and military experience.

A very special appreciation is extended to Audrey Shively, MSHSE, MCHES, CCMEP, Director, Education, of the AAO-HNS Foundation, for her unwavering efforts on behalf of this project, and her competent and patient management of the mechanics of the Resident Manual's production. Additionally, this manual could not have been produced without the expert copyediting and design of diverse educational chapters into a cohesive, concise, and practical format by Joan O'Callaghan, Director, Communications Collective, of Bethesda, Maryland.

The editors also wish to acknowledge the unwavering support and encouragement from: Rodney P. Lusk, MD, President; David R. Nielsen, MD, Executive Vice President and CEO; Sonya Malekzadeh, MD, Coordinator for Education; and Mary Pat Cornett, CAE, CMP, Senior Director, Education and Meetings, of the AAO-HNS/F. We also appreciate the administrative support of Rudy Anderson as AAO-HNS/F Staff Liaison for the Trauma Committee.

Since it takes a group of dedicated professionals to produce an educational and clinical manual such as this, all have shared in the effort, and each individual's contribution has been outstanding.

**G. Richard Holt, MD, MSE, MPH, MABE**  
*Editor and Chair*  
*Task Force on Resident Trauma Manual*

**Joseph A. Brennan, MD, Colonel, MC, USAF**  
*Chair*  
*AAO-HNS Committee on Trauma*

## Resident Trauma Manual Authors

### **Joseph A. Brennan, MD, Colonel, MC, USAF**

Chair, AAO-HNS Committee on Trauma  
Chief, Department of Surgery  
San Antonio Military Medical Center  
Fort Sam Houston, Texas

### **G. Richard Holt, MD, MSE, MPH, MABE**

Chair, Task Force on Resident Trauma Manual  
Professor Emeritus, Department of Otolaryngology-Head and Neck Surgery  
University of Texas Health Science Center  
San Antonio, Texas

### **Matthew P. Connor, MD, Captain, MC, USAF**

Resident Physician, Department of Otolaryngology-Head and Neck Surgery  
San Antonio Uniformed Services Health Education Consortium  
Fort Sam Houston, Texas

### **Paul J. Donald, MD**

Professor and Vice Chair, Department of Otolaryngology  
University of California-Davis Medical Center  
Sacramento, California

### **Vincent D. Eusterman, MD, DDS**

Director, Otolaryngology-Head and Neck Surgery  
Denver Health Medical Center  
Denver, Colorado

### **David K. Hayes, MD, Colonel, MC, USA**

Chief of Clinical Operations, US Army Southern Regional Medical Command  
San Antonio Military Medical Center  
Fort Sam Houston, Texas

### **Robert M. Kellman, MD**

Professor and Chair, Department of Otolaryngology and Communication Sciences  
State University of New York Upstate Medical Center  
Syracuse, New York

### **John M. Morehead, MD**

Associate Professor and Program Director  
Department of Otolaryngology-Head and Neck Surgery  
University of Texas Health Science Center  
San Antonio, Texas

**Mark D. Packer, MD, Colonel (P), MC, FS, USAF**

Director, DOD Hearing Center of Excellence  
Chief, Neurotology, Cranial Base Surgery  
San Antonio Military Medical Center  
Fort Sam Houston, Texas

**Whitney A. Pafford, MD**

Resident Physician, Division of Otolaryngology  
New York University School of Medicine  
New York, New York

**Mitchell Jay Ramsey, MD, Lt Colonel, MC, USA**

Chief Otology/Neurotology  
Landstuhl Kaiserlautern Army Medical Center  
Germany

**Nathan L. Salinas, MD, Captain, MC, USA**

Chief, Department of Otolaryngology  
Bassett Army Community Hospital  
Ft. Wainwright, Alaska

**Joseph C. Sniezek, MD, Colonel, MC, USA**

Otolaryngology Consultant to the Surgeon General of the Army  
Tripler Army Medical Center  
Honolulu, Hawaii

**Christian L. Stallworth, MD**

Assistant Professor, Facial Plastic and Reconstructive Surgery  
Department of Otolaryngology-Head and Neck Surgery  
University of Texas Health Science Center  
San Antonio, Texas

**Matthew Scott Stevens, MD**

Resident Physician, Department of Otolaryngology-Head and Neck  
Surgery  
University of Texas Health Science Center  
San Antonio, Texas

**Richard W. Thomas, MD, DDS, Major General, MC, USA**

Otolaryngologist-Head and Neck Surgeon  
Commanding General, Western Region Medical Command  
Joint Base Lewis-McChord, Washington

## Chapter 5: Mandibular Trauma

Vincent D. Eusterman, MD, DDS

Mandible fractures are among the most common skeletal injuries in man due to blunt or penetrating trauma. They are often associated with other craniofacial, cervical, and systemic trauma. Mandibular fractures may destabilize the airway and may create malocclusion, joint dysfunction, pain, infection, and paresthesia. In facial trauma management, emergent consideration must be given to secure the airway and obtain hemostasis before initiating definitive treatment of any fracture.

Historically, treatment of the fractured mandible dates to 1650 BC on Egyptian papyrus detailing the examination, diagnosis, and treatment. Since then, many ingenious methods and devices for fracture treatment have included the facial bandage,<sup>1,2</sup> extraoral and intraoral appliances,<sup>3</sup> arch bars,<sup>4,5</sup> and wire and plate osteosynthesis.<sup>6-8</sup>

Mandibular fractures are sites described as in the horizontal mandible or the dentoalveolar fractures and the vertical mandible with fractures of the mandibular angle, ramus, condyle, and coronoid processes. The mandible is an active mobile articulation with the maxillary dentition. Fracture treatment concerns include malocclusion, infection, joint dysfunction, growth retardation, nonunion, and facial nerve injury. Pediatric mandibular fractures are managed differently due to the mixed dentition, anatomic differences in teeth, and intrinsic makeup of the pediatric mandible.

### I. Mandibular Bone, Muscle, and TMJ Anatomy

#### A. MANDIBULAR BONE

This vulnerable, v-shaped cartilaginous bone articulates at each at the temporomandibular joint (TMJ). The horizontal mandible is divided structurally into basal bone and alveolar (tooth bearing) bone, and consists of the symphysis, parasymphysis, body, and alveolar bone. The vertical mandible consists of the angle, ramus, condylar, and coronoid processes.

#### B. MANDIBULAR MUSCLE

Paired lateral pterygoid muscles open the jaw. The upper head originates on the infratemporal surface and crest of the greater wing of the sphenoid bone and inserts onto the articular disc and fibrous capsule of the TMJ. The lower head originates on the lateral surface of the lateral



pterygoid plate and inserts onto the neck of the mandibular condyle. Fractures of the condyle are pulled anterior-medially by this muscle.

Three paired muscles close the mandible. The medial pterygoid muscle from the medial portion of the lateral pterygoid plate and the masseter muscle from the zygomatic process of the maxilla, and anterior two-thirds of the lower border of the zygomatic arch, insert on the medial and lateral vertical mandible forming a tendinous “pterygomassitic sling.” The temporalis muscle arises from the temporal fossa and the deep part of temporal fascia and passes medial to the zygomatic arch and inserts onto the coronoid process of the mandible.

### **C. TEMPOROMANDIBULAR JOINT**

The TMJ’s articular eminence and superior condyle are covered with fibrocartilage. The articular disk is dense collagenous connective tissue and is without sensation. The retrodiscal loose connective tissue that anchors the disk posteriorly is well innervated, and when torn, allows the disk to displace anteriorly.

The jaw opens in two steps: (1) the condyle rotates in the inferior joint space for an interincisor opening of 20–24 millimeters (mm), and (2) the condyle and disk translate down the articular eminence, allowing the interincisor opening to exceed 40 mm.

## **II. Indications of the Presence of Mandibular Fracture**

### **A. SYMPTOMS (SUBJECTIVE)**

- Pain.
- Bite abnormality.
- Numbness.
- Bleeding.
- Swelling.
- Dyspnea.

### **B. SIGNS (OBJECTIVE)**

#### **1. Deformity**

External deformity is often difficult to see clinically due to swelling. Intraoral exam may show displacement creating a step deformity, open bite deformity, and malocclusion. Many patients can have significant preexisting malocclusion, which must be documented in preoperative notes and considered during treatment planning.

## CHAPTER 5: Mandibular Trauma

### 2. Pain

Fracture sites are tender to palpation and sometimes to compression. Tapping the chin will compress the fracture and may elicit pain at the site. TMJ pain under compression may identify a fractured condyle or a contused and inflamed joint.

### 3. Tooth and Bone Fragment Hypermobility

Tooth and bone fragment hypermobility are signs of mandibular fracture. Airway compromise can occur with either posterior tongue displacement in bilateral mandibular fractures producing “flail mandible” or with traumatic tongue muscle avulsion.

### 4. Bleeding, Hematoma, and Swelling

Tearing of the periosteum and muscles attached to the mandible can cause significant bleeding, producing visible hemorrhage, sublingual hematoma, swelling, and life-threatening airway compromise. Urgent intubation, and infrequently tracheostomy, may be required to maintain respiration.

### 5. Crepitus

Crepitus is the sound produced by the grating of the rough surfaces when the bony ends come into contact with each other.

### 6. Restricted Function

Restricted functions include lateral deviation on opening to the side of fracture, inability to chew, loss of opening (lockjaw) due to muscle splinting, trismus, joint dysfunction, or impingement by zygomatic fractures.

### 7. Sensory Disturbances

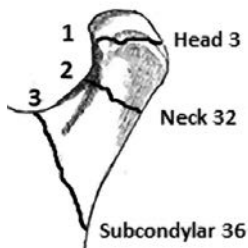
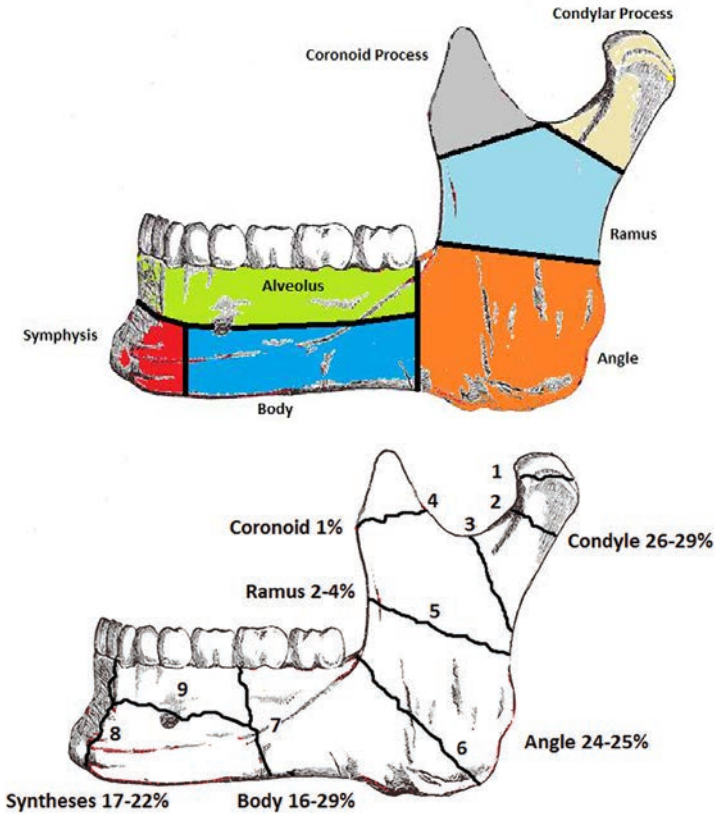
The inferior alveolar nerve (V3) courses through the mandibular body and angle. Fractures of the bony canal can cause temporary or permanent anesthesia of the lip, teeth, and gingiva. The lingual nerve (V3) lies close to the lingual cortex near the mandibular third molar. Injury may cause temporary or permanent anesthesia to the ipsilateral tongue and gingiva.

## III. Classification of Mandibular Fractures

Mandibular fractures are most commonly referred to their anatomic location as symphyseal, parashymphyseal, body, angle, ramus, alveolar, condyle, or coronoid (Figures 5.1 and 5.2). Table 5.1 provides additional descriptors regarding severity and displacement that can help in treatment planning.

**Figure 5.1**

Top: anatomic regions of the mandible. Bottom: mandibular fracture sites, condylar head (1), condylar neck (2), subcondylar (3), coronoid (4), ramus (horizontal or vertical) (5), angle (6), body (7), syntheses (synthesis and parasynthesis) (8), alveolar (9), and most common fracture locations.



**Figure 5.2**

Mandibular condyle with classification and distribution of fractures—condylar head, condylar neck, subcondylar.<sup>9-12</sup>

**Table 5.1. Descriptors Regarding the Severity and Displacement of Mandibular Fractures**

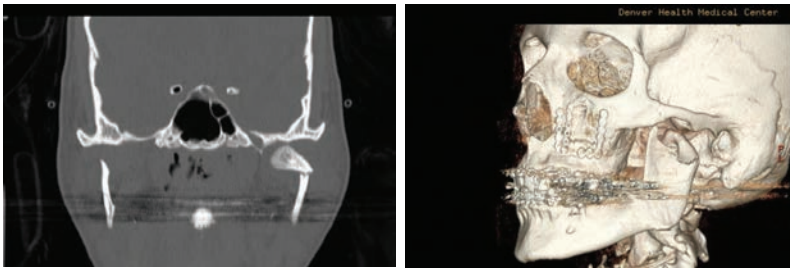
Fracture Terminology	Fracture Description
Compound or open fractures	Exposed to contaminated oral secretions usually involving erupted teeth.
Simple or closed fractures	Not exposed to oral secretions; usually nontooth-bearing bone.
Favorable fracture	Not distracted by muscle pull; requires less fixation.
Unfavorable fracture	Distracted by muscle pull; may require greater fixation to resist muscle pull.
Comminuted fracture	Crushed, fragmented, or splintered.
Complicated or complex fracture	Associated with significant injury to the adjacent soft tissues.
Multiple fractures	Two or more noncommunicating fractures on the same bone.
Indirect fracture	Located at a point not in alignment with or distant from the site of injury.
Impacted fracture	One fragment is driven firmly into the other fragment.
Greenstick fracture	One bony cortex is broken, and the other cortex is bent.
Pathologic fracture	Occurs through bone weakened by preexisting disease.
Atrophic fracture	From bone atrophy by loss of supporting alveolar bone in edentulous mandibles.

### A. CONDYLE FRACTURES

Condyle fractures are considered the most common fracture of the mandible. They are divided into the head, neck, and subcondylar regions (Figures 5.1 and 5.2).

Lindahl, Spiessl and Schroll, Krenkel, and Neff proposed complex condyle fracture classifications.<sup>10,11,13-15</sup> Ellis et al. classified condylar fractures as condylar head fracture (intracapsular fracture located at the border between the condylar head and neck), condylar neck fracture (located below the condylar head but on or above the lowest point of the sigmoid notch), and condylar base fracture (the fracture line isolated below the lowest point of the sigmoid notch).<sup>16</sup>

Most condylar fractures are currently treated closed (Figures 5.3). Evidence supporting open reduction of condylar fractures is growing, specifically subcondyle fractures and endoscopic techniques. Zide and Kent list absolute and relative indications for open reduction of the fractured mandibular condyle.<sup>17</sup> Palmieri and Throckmorton<sup>18</sup> and De Riu et al.<sup>19</sup> demonstrated better long-term range of motion and occlusion in patients with condylar fractures treated with open reduction and internal fixation (ORIF) versus closed reduction and maxillomandibular fixation (MMF). Absolute and relative indications are listed below under section V, Surgical Management.



**Figure 5.3**

Coronal and 3-D image of a left condyle fracture. In addition, the patient had a Le Fort I fracture and was treated with midface plating and MMF. She recovered mandibular range of motion and pretraumatic occlusion without open reduction of the condyle.

### **1. Condylar Head or Intracapsular Fractures**

Condylar head fractures are rarely encountered in adults. Prevalent clinical judgment is that MMF is generally contraindicated because of the high risk for TMJ ankylosis. Computed tomography (CT) scanning provides the most information about intracapsular fractures.

### **2. Condylar Neck and Subcondylar Fractures**

Condylar neck and subcondylar fractures are the most common mandibular fractures in adults (Figure 5.1). Subcondylar fractures are below the condylar neck. Fractures here enter the sigmoid notch and may be considered “high or low,” depending on the site of exit of the posterior extension of the fracture.

Most subcondylar fractures are also treated conservatively, using a closed approach to avoid complications. Subcondylar fractures offer sufficient bone stock for ORIF.

### B. FRACTURES OF THE MANDIBULAR ANGLE

The mandibular angle is the pie shaped area with its apex at the distal 3<sup>rd</sup> molar, also the site of the masseter attachment (Figure 5.1).

Fractures of this angle are common. They occur in 25 percent of adult fractures and result from the area weakened by the third molar tooth.

### C. FRACTURES OF THE MANDIBULAR BODY

The mandibular body is the horizontal mandible from distal symphysis to a vertical line distal to the 3<sup>rd</sup> molar tooth (Figure 5.1). Mandibular body fractures, such as symphyseal fractures, involve the dentition and require special attention to ensure an adequate occlusal reconstruction as well as bony repair.

Body fractures and angle fractures will be affected by muscle pull, which can produce a favorable fracture by reducing the fracture or an unfavorable fracture if the depressors and elevator muscles distract the fracture.

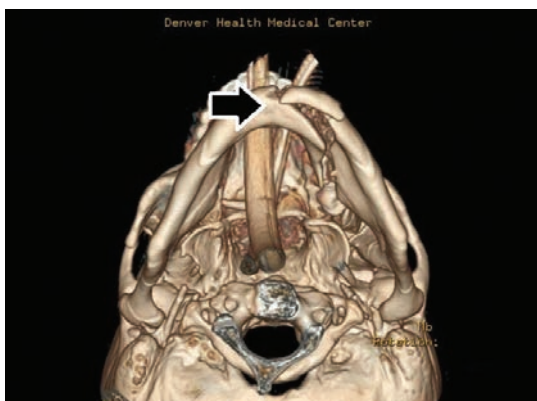
### D. FRACTURES OF THE SYMPHYSIS AND PARASYMPHYSIS

The symphysis is the area between vertical lines drawn distal to the mandibular canine teeth. Symphyseal and parasymphyseal fractures are usually caused by direct trauma to the chin, such as a fall that bends the mandible.

- A *symphyseal fracture* is a midline mandibular fracture between the central incisors.
- A *parasymphyseal fracture* is a non-midline fracture occurring within the symphysis.
- *Masseter muscle pull* will cause lingual displacement and rotation of the teeth. It will distract the fracture site, often causing a lingual splay, which requires overbending of the plate to adequately reduce the fracture (Figure 5.4).

#### Figure 5.4

A submental view of a comminuted parasymphyseal fracture (black arrow) and loss of v-shaped mandible and lingual splaying. Repair must include overbending of the buccal bone plates to reduce the lingual splay.



- *Canine area fractures* follow the bone weakened by the long canine tooth.
- *Bilateral fractures* may cause posterior displacement of the tongue and airway compromise. They may also involve the contralateral condyle fractures in up to 37 percent of the cases.<sup>20</sup>
- Children often have a *greenstick fracture* of the mandibular cortex.

### **E. FRACTURES OF THE RAMUS**

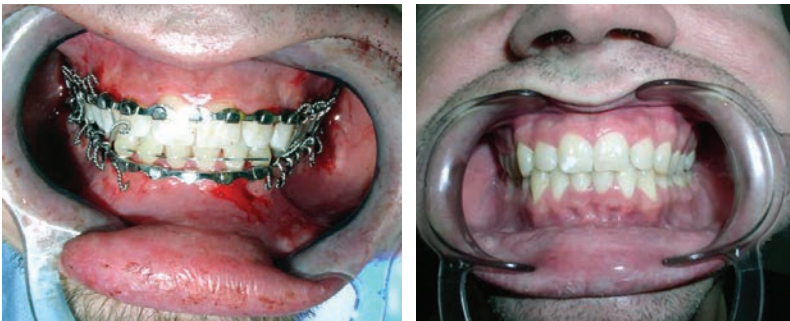
The ramus is the vertical portion of the mandible above the horizontal plane of the alveolar ridge, ending at the sigmoid notch. Fractures in the ramus are rare. They can be vertical, but are more often horizontal.

### **F. FRACTURES OF THE CORONOID**

The coronoid process is anterior-superior to the ramus. It serves as the attachment of the temporalis muscle. Coronoid fractures are rare and usually do not require treatment, unless they are involved in an impingement from a zygomatic fracture.

### **G. ALVEOLAR (DENTOALVEOLAR) FRACTURES**

The alveolar bone houses the dentition. This bone atrophies in the absence of teeth. Dentoalveolar fractures are common, but isolated alveolar fractures are rare. Dental luxation and alveolar segments may be fixated in the MMF, by separate ligatures, or by wire composite splinting, as seen in Figure 5.5.



**Figures 5.5**

Left, mandibular incisors region dental alveolar fracture held in place with wire-composite splint between canine teeth and MMF. Right, post-treatment photograph of intact dentition and bite, with retained lower incisors following dentoalveolar fracture.

## H. EDENTULOUS FRACTURES

### 1. Closed Reduction

A patient's dentures can be used as a splint, secured by circummandibular wires, circumzygomatic wires, nasal pyriform wires, or palatal screws.<sup>21</sup> When the denture is not available, a Gunning splint can be fabricated with built-in arch bars, as well as an anterior opening for feeding. This is secured in the same fashion as wiring the patient's denture to the mandible.

Biphasic external pin fixation or Joe Hall Morris appliance may be indicated for a discontinuity defect, for severely comminuted fractures, or when maxillomandibular or rigid fixation cannot be used.

### 2. Open Reduction

The complication rate for open reduction of the edentulous mandible is significant when the load is shared with small bone plates. To minimize the complication rate, the atrophic mandible requires a load-bearing repair using strong plates with multiple fixation points using bicortical screws.

Ellis and Price advocate an aggressive protocol of ORIF with rigid fixation and acute bone grafts. They demonstrated no complications with this approach, despite the advanced age and medical comorbidities of this patient population.<sup>21</sup>

## IV. Diagnostic Evaluations

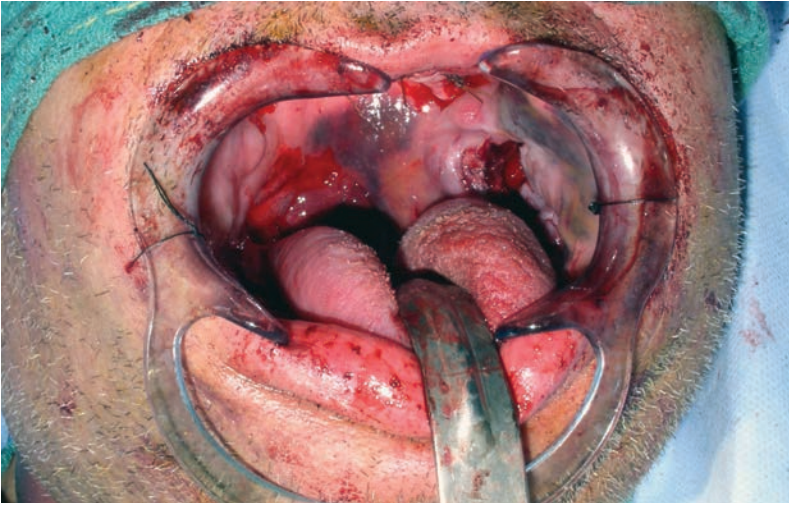
### A. FULL-BODY TRAUMA ASSESSMENT

Mandibular fractures are too often a small portion of a larger trauma picture. The traumatized patient is best served from a trauma team approach. Once the advanced trauma life-support protocols have been instituted, the airway has been stabilized, and breathing, circulation, and neurological status have been addressed, the secondary surveys can be initiated. The intact mandible supports the airway by anterior tongue attachment. The fractured mandible may risk the support of the tongue, and hemorrhage into the sublingual and submandibular spaces can cause the loss of the airway (Figures 5.6 and 5.7).

### B. TRAUMA HISTORY

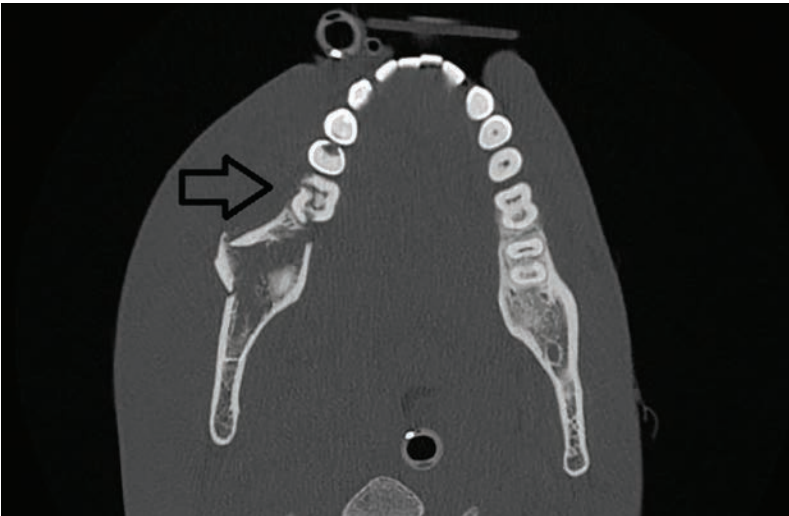A complete medical and psychiatric history is important for diagnosis and treatment planning. Medical history should include identification of the following prior to surgery: previous mandibular trauma, occlusal abnormalities, TMJ disease, and bleeding, endocrine, neurological,





**Figure 5.6**

Large progressive submandibular hemorrhage from a fractured mandible required urgent airway management.



**Figure 5.7**

Comminuted body and tooth fractures following a blow with a metal pipe. Mandibular fractures generally correspond to the "type of injury," in this case producing comminuted bone and tooth fractures from a hard object. This patient required urgent intubation due to loss of the airway from submandibular hemorrhage.

## CHAPTER 5: Mandibular Trauma

bone, and collagen disorders. The site (chin, body), direction and size, and source (fist, pipe) of the traumatic force are very helpful in identifying direct and indirect fractures of the mandible.

### C. HEAD AND NECK EXAMINATION

Evaluate the entire head and neck for facial lacerations, swellings, and hematomas. A common site for a laceration is under the chin. This should alert the clinician to the possibility of an associated subcondylar or symphysis fracture.

From behind the supine or seated patient, bimanually palpate the inferior border of the mandible from the symphysis to the angle on each side. Note areas of swelling, step deformity, or tenderness. Note areas of anesthesia along the distribution of the inferior alveolar nerve. Numbness in this region is almost pathognomonic of a fracture distal to the mandibular foramen.

Standing in front of the patient, palpate the movement of the condyle through the external auditory meatus. Pain elicited through palpation of the preauricular region should alert the clinician to a possible condylar fracture.

### D. ORAL EXAMINATION

Identify deviation on opening of the mouth. Deviation on opening is toward the side of a mandibular condyle fracture. Record inter-incisor opening.

Identify limited opening (trismus) from reflex muscle, TMJ edema, or coronoid impingement from a depressed zygomatic fracture. Changes in occlusion are highly suggestive of a mandibular fracture. A change in occlusion may be due either to a displaced fracture, fractured teeth, and alveolus or to injury to the TMJ.

Tears in the unattached mucosa or attached gingiva and ecchymosis in the floor of the mouth usually indicate a mandibular symphyseal or body fracture. If a mandibular fracture is suspected, grasp the mandible on each side of the suspected site and gently manipulate it to assess mobility.

### E. OCCLUSAL EVALUATION

#### 1. Angle Class I Occlusion

Angle Class I occlusion is the normal anteroposterior relationship of the mandible to the maxilla. The mesiobuccal cusp of the permanent

maxillary first molar occludes in the buccal groove of the permanent mandibular first molar (Figure 5.8).

## 2. Angle Class II Occlusion

Angle Class II occlusion is the posterior relationship of the mandible to the maxilla. The mesiobuccal cusp of the permanent maxillary first molar occludes *mesial* to the buccal groove of the permanent mandibular first molar.

## 3. Angle Class III Occlusion

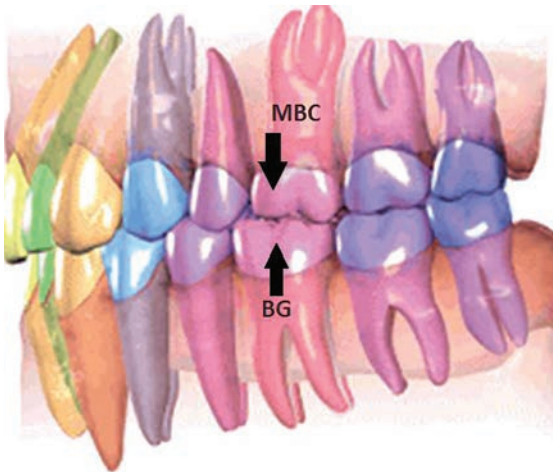
Angle Class III occlusion is the anterior relationship of the mandible to the maxilla. The mesiobuccal cusp of the permanent maxillary first molar occludes *distal* to the buccal groove of the permanent mandibular first molar.

## 4. Maximum Intercuspatation

Maximum intercuspation refers to the occlusal position of the mandible in which the cusps of the teeth of both arches fully interpose themselves with the cusps of the teeth of the opposing arch. This position is the goal in repositioning the teeth in proper occlusion during MMF.

## 5. Wear Facets

A wear facet is a highly polished wear pattern or spot on a tooth produced by an opposing tooth from chewing or grinding. It is useful in repositioning teeth into premorbid occlusion when a pre-existing malocclusion was present (crowding, spacing, midline misalignment).



**Figure 5.8**

Molar relationship in Class I occlusion, mesiobuccal cusp (MBC) of the upper first molar occludes with the buccal groove (BG) of the lower first molar.

## CHAPTER 5: Mandibular Trauma

### 6. Overjet and Overbite

Overjet is anterior vertical overlap, and overbite is anterior horizontal overlap. Both are measured in millimeters.

### 7. Skeletal Malocclusion

Skeletal disharmony of the maxillary and mandibular relationship, as identified on cephalometric assay, produces malocclusion of the upper and lower dentition. Most skeletal malocclusions can only be treated by orthognathic surgery.

### 8. Dental Malocclusion

Dental malocclusion is the misalignment of teeth or incorrect relation between the teeth of the maxilla and mandible. This term was coined by Edward Angle, the “father of modern orthodontics,” as a derivative of occlusion, which refers to the way opposing teeth meet. Most dental malocclusions are treated by orthodontic movement.<sup>22</sup>

### 9. Mesial

Mesial refers to the direction toward the anterior midline in a dental arch. Each tooth can be described as having a mesial surface and, for posterior teeth, a mesiobuccal and a mesiolingual corner or cusp.

### 10. Distal

Distal refers to the direction toward the last tooth in each quadrant of a dental arch. Each tooth can be described as having a distal surface and, for posterior teeth, a distobuccal and a distolingual corner or cusp.

### 11. Crossbite

A crossbite is a malocclusion where a single tooth or a group of teeth has a more buccal or lingual position and can be classified in anterior or posterior and bilateral or unilateral. Anterior crossbite is seen in Angle Class III skeletal malocclusion, while posterior crossbite correlates to a narrow maxilla.

### 12. Centric Occlusion and Centric Relation

Centric occlusion is the occlusion of opposing teeth when the mandible is in centric relation to the maxilla. Centric occlusion is the first tooth contact and may or may not coincide with maximum intercuspation. It is also referred to as a person’s habitual bite position. Centric relation should not be confused with centric occlusion, which is the relationship between the maxilla and mandible.

### 13. Vertical Dimension of Occlusion

This term is used in dentistry to indicate the superior-inferior relationship (height) of the maxilla and the mandible when the teeth are

situated in maximum intercuspation. Loss of facial and dental vertical dimension occurs with the loss of teeth.

#### 14. Identification of Adult and Pediatric Teeth

Adult teeth are numbered from 1 to 32, from the upper right to the lower right. Teeth that are in malocclusion or that have been lost to trauma should be identified, along with all missing teeth.

Pediatric teeth are lettered from A to T (20 teeth), also from the upper right to the lower right.

### F. IMAGING STUDIES

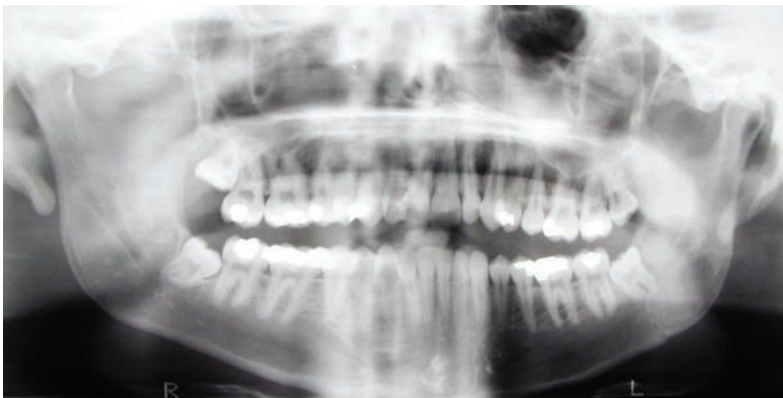
#### 1. Mandible Series

Three films are used for isolated mandibular fractures:

- A posteroanterior (PA) showing a PA view of angle and ramus fractures.
- A reverse Towne of a PA view, showing medial/lateral displacement of condyle and subcondylar fractures.
- Bilateral oblique views for body and angle fractures.

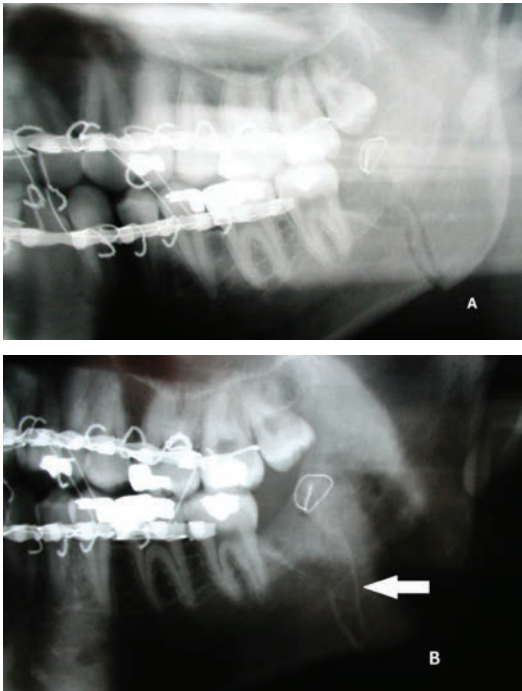
#### 2. Panorex

Panorex is a panoramic tomographic scan that shows the entire mandible, including condyles, on one film. It is an excellent screening evaluation study for the patient who is able to stand or sit upright without motion. Panorex offers low radiation, low cost, and excellent detail, and is excellent for follow-up evaluation (Figures 5.9 and 5.10).



**Figure 5.9**

Panorex film demonstrates a planar view of dentition, mandible, and condyles. Patient has a left angle fracture and widening of the periodontal ligament space on tooth #17.



**Figure 5.10**

Follow-up Panorex films of left angle fracture from Figure 5.9. (A) After MMF and wire osteosynthesis. (B) Postoperative check at 4 weeks, showing excellent healing and callus formation (white arrow).

### 3. CT Scan

A CT scan is ideal when visualization is difficult, especially visualization of the condylar head and high condylar neck. CT is generally the preferred method of imaging for multiple mandibular fractures, and is especially helpful in the multiply traumatized patient requiring images of the cervical spine, cranium, and carotid arteries. Also, 3-D CT scanning capabilities add immeasurably to the diagnosis and treatment planning of complex facial fractures.

### 4. MRI Scan

Magnetic resonance imaging (MRI) is better for evaluating soft-tissue disease, such as hematoma and complications of trauma.

### 5. Occlusal View

An occlusal view will show symphysis fractures.

### 6. Periapical Radiographs

Periapical radiographs show dental root fractures next to mandible and alveolar fractures.

## V. Surgical Management

### A. INDICATIONS FOR SURGERY

All mandibular fractures require some form of treatment, from soft diet to open reduction, and internal fixation with bone grafting. The type of treatment will depend on the severity of the fracture and whether additional facial bone fractures are present. The general treatment decision will be between open or closed fracture reduction.

The ability to treat fractures with ORIF has changed dramatically in recent years. Traditional 6-week treatment of closed reduction with MMF or open reduction with wire osteosynthesis and MMF has given way to early mobilization and restoration of jaw function, improved airway control, improved nutrition, improved patient comfort and hygiene, and an earlier return to work.<sup>23-25</sup> Some studies have shown that it may be more cost-effective to treat patients “at risk for” mandibular fracture with closed reduction treatment.<sup>26,27</sup> It has been our experience that the “at risk” unpredictable patient may be better off by not having removable hardware that can be removed or poorly maintained.

#### 1. Indications for Closed Reduction

##### a. *Nondisplaced Favorable Fractures*

Nondisplaced favorable fractures should be treated by the simplest method to reduce and fixate.

##### b. *Pediatric Fractures*

In pediatric fractures involving the developing dentition, open reduction can injure developing tooth buds or partially erupted teeth.<sup>28</sup> Pediatric condyle fractures are best managed by closed reduction and early mobilization after 2–3 weeks of MMF.

##### c. *Grossly Comminuted Fractures*

Grossly comminuted fractures can be treated by closed reduction to minimize periosteal stripping of bone fragments.

##### d. *Coronoid Fractures*

Coronoid fractures are rarely treated, unless there is impingement on the zygomatic arch.

##### e. *Adult Condyle Fractures*

Adult condyle fractures are controversial topics in maxillofacial trauma. Closed treatment is generally the appropriate choice, unless the patient

## CHAPTER 5: Mandibular Trauma

meets Valiati et al.'s criteria for open treatment.<sup>29</sup> If condylar fractures do not fall within these criteria, the patient can be treated with closed reduction for 2–3 weeks. When a condylar fracture is in association with other fractures of the mandible, the other fractures should be treated with ORIF, and the condylar fracture should be treated with closed reduction.

### 2. Contraindications to Closed Reduction

Contraindications to closed reduction MMF include patients with compromised pulmonary function with severe asthma or severe chronic obstructive pulmonary disease, poorly controlled seizures, psychiatric or neurologic disorders, and severe nausea or eating disorders.

### 3. Indications for Open Reduction

- Displaced unfavorable fractures through the angle of the mandible.<sup>30</sup>
- Atrophic edentulous mandibles, minimal cancellous bone, and poor osteogenesis and healing potential.
- Complex facial fractures requiring a stable mandibular base. These fractures require the mandibular segments to be reconstructed first with open reduction and fixation.
- Condylar fractures. While condylar fractures are generally treated with closed reduction, a specific group of individuals benefits from surgical intervention. Table 5.2 lists the absolute and relative indications for open reduction of the fractured mandibular condyle.<sup>17</sup> The relative indications remain a choice between surgical expertise and the desires of the patient.

## B. TIMING OF SURGICAL PROCEDURES

Mandibular fractures involving teeth are considered open, and should be treated in the preoperative period with antibiotics to reduce the risk of infection.<sup>32,33</sup> Traditional teaching recommends treatment within 24 hours of injury.<sup>34</sup> However more recent studies have shown no increase in complications due to delays in repair beyond 24 hours, although there may be an increase in technical complications of the repair.<sup>35–40</sup>

## C. SURGICAL EXPOSURE OPTIONS

Surgical exposure of the mandible is determined by the fracture type and location.



**Table 5.2. Absolute and Relative Indications for Open Condyle Reduction**

Absolute Indications	Relative Indications
Displacement of the condyle into the middle cranial fossa or external auditory canal.	Bilateral condylar fractures in an edentulous patient when splints are unavailable or impossible because of alveolar ridge atrophy.
Inability to obtain adequate occlusion. <sup>20</sup>	Bilateral or unilateral condylar fractures when splinting is not recommended because of concomitant medical conditions or when physiotherapy is not possible.
Lateral extracapsular dislocation.	Bilateral fractures associated with comminuted midface fractures.
Contaminated open joint wound.	Bilateral subcondylar fractures with associated: <ul style="list-style-type: none"><li>▪ retrognathia or prognathism,</li><li>▪ open bite with periodontal problems or lack of posterior support,</li><li>▪ loss of multiple teeth and later need for reconstruction,</li><li>▪ unstable occlusion due to orthodontics, and</li><li>▪ unilateral condylar fracture with unstable fracture base.</li></ul>

Source: Zide and Kent.<sup>17</sup>

The primary objectives of surgical reconstruction of the mandible are that access and reconstruction be tailored to meet the demand of the fracture repair. Simple fractures demand little or no access and should be treated in a simple closed fashion. More complex fractures that demand ORIF with plate osteosynthesis require careful planning to avoid cranial nerve injury, periosteal loss, and facial scarring. Reduction and fixation are adequate for the site to reduce the risk of nonunion, malunion, and malocclusion.

The mandible is separated into multiple areas anatomically (Figure 5.1). Each fractured region has unique qualities, depending on the extent of the fracture, the stresses placed on the fractured bone by muscles, the size and strength and healing ability of the bone at that site, oral contamination, and the overlying structures complicate a repair approach. Treatment of mandible fractures will be divided into closed and open fracture reduction and soft tissue approaches to the mandible.

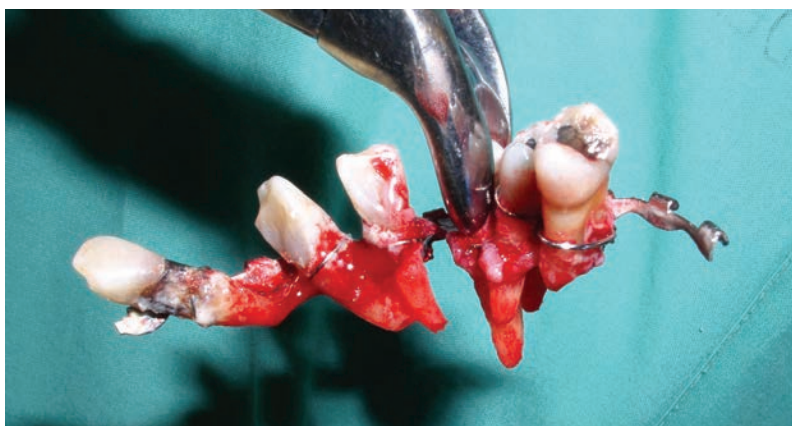
## CHAPTER 5: Mandibular Trauma

### 1. Closed Reduction

Closed reduction can be accomplished with a variety of techniques with and without the dentition. When teeth are present, circumdental wire, arch bars, IMF screws, acid etch brackets are used.

#### *a. Erich Arch Bars*

Arch bars are considered the standard in MMF. These are cut and fitted on both dentitions. If intended for long term use, patients must be aware of the risks to teeth and periodontum and have adequate follow-up care (Figure 5.11).



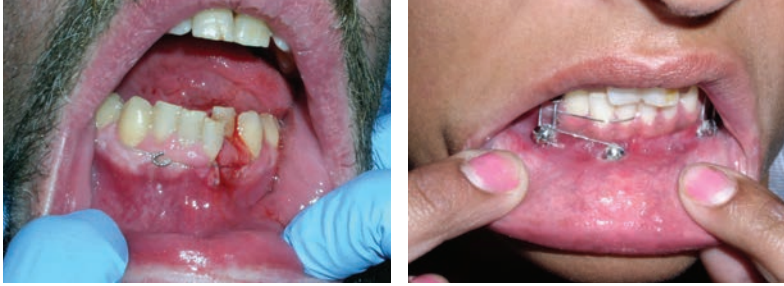**Figure 5.11**

Photo of arch bars retained in a patient for 4 years who had forgotten to make a follow-up appointment.

- Start by counting 18 lugs.
- Position the bars so the lugs open away from the crowns to allow MMF wires.
- Use 24-gauge stainless steel circumdental wires twisted closed in a clockwise rotation. Wires may be prestretched to lessen wire stretching and loosening after surgery. Factory-cut wires may be less sharp and may lessen the risk of puncture injury.
- Position the patient into maximum intercuspation, and place MMF wires or elastics.

### **b. Bridle Wire**

Bridle wire is a single ligature placed for temporary stabilization of mobile fractures (Figure 5.12). Bridle wire is often placed under local anesthesia. Teeth adjacent to the fracture should be avoided.

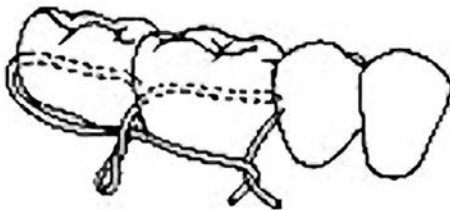


**Figure 5.12**

Bridle wire placed to reduce discomfort is stabilizing a parasymphyseal fracture (left). Bridle wire and IMF screws are stabilizing a nondisplaced parasymphyseal fracture (right).

### **c. Ivy Loops**

Ivy loops are used for MMF for minimally displaced fractures when the full patient has a full dentition. The loop is constructed with 24-gauge wire. A small loop is made in the center of the wire (Figure 5.13). The loose ends are passed through the interproximal of two stable teeth, brought around the mesial and distal interproximal of each tooth. The distal wire is brought under (or through) the loop and anchored to the mesial wire with a clockwise twist. An opposing loop is then created to make a pair. The loop produced is then used to pass a third 24-gauge wire to anchor the MMF wire. A minimum of two sets of Ivy loops is recommended bilaterally.



**Figure 5.13**

Ivy loop passed between the interproximal space of #30 and #31.

## CHAPTER 5: Mandibular Trauma

### **d. IMF Screws**

IMF screws are 2.5-mm stainless steel self-drilling and -tapping screws in 8- and 12-mm lengths. These temporary screws are used for minimally displaced fractures when the patient has a full dentition. They are placed in the anterior jaw in the unattached mucosa on either side of the canine teeth roots. Care is taken not to compress the gingiva or damage tooth roots. If placing the screws posteriorly on the mandible, the mental nerve must be avoided. Also, the infraorbital nerves may be injured if the screws are placed too high on the maxilla.

## **2. Open Reduction**

Surgical approaches must be tailored to meet the demand of the soft tissue and bony fracture repair. The ideal osteosynthesis system of mandibular fractures must meet hardness and durability criteria to handle functional changes and allow bone healing.

### **a. Use of Existing Lacerations**

Soft tissue injuries often accompany facial fractures and can be used to directly access the fractured bone for open repair.

### **b. Intraoral Approach**

Advantages of an interoral approach include expediency, no facial scar, low risk to facial nerve, and performed under local anesthesia.

#### *i. Labial Sulcus Incision*

Symphysis and parasymphysis fractures are easily accessed through a labial sulcus incision. The mental nerve is identified between the roots of the first and second bicuspid.

Labial sulcus incision can be made on the lip vestibular mucosa through the mentalis muscle then to the bone. This incision improves a watertight closure and reduces saliva contamination by having the closure out of the sulcus. In addition, postoperative chin tape can compress the dead space over the chin.

#### *ii. Vestibular Incision*

Body, angle, and ramus fractures can be accessed through a vestibular incision that may extend past the external oblique line to the mid-ramus. The ramus and the subcondylar region can be exposed by stripping and elevating the buccinator muscle and temporalis tendon at the coronoid process with a lighted notched ramus retractor.

### **c. Submental and Submandibular Approach**

The submental approach is used to treat fractures of the anterior mandibular body and symphysis.

The submandibular approach was described by Risdon in 1934.<sup>41,42</sup>

- Make the incision 2 centimeters (cm) below the angle of the mandible in a natural skin crease.<sup>43</sup>
- Dissect through skin, subcutaneous fat, and superficial cervical fascia to expose platysma muscle.
- Dissect the platysma, identify the superficial layer of the deep cervical fascia. The marginal mandibular nerve is deep to this layer.<sup>44</sup>
- Dissect through deep cervical fascia with the aid of a nerve stimulator/monitor to the mandibular bone.
- Dissect down to the level of the pterygomassitic sling, dividing it to expose bone.

#### **d. Retromandibular Approach**

The retromandibular approach was described by Hinds in 1958.<sup>45,46</sup>

- Make a vertical incision 0.5 cm below the lobe of the ear, and continue it inferiorly 3.0–3.5 cm. It should be behind the posterior mandibular border and should extend to the level of the angle.
- Dissect through the platysma and superficial musculoaponeurotic layer and parotid capsule.
- Consider using the aid of a nerve stimulator or facial nerve monitor, as the marginal mandibular branch and the cervical branch of the facial nerve may be encountered here.
- The retromandibular vein runs vertically in the parotid and should be identified and ligated or retracted to gain access to the lateral mandible.
- Sharply incise the pterygomasseteric sling and elevate the muscle off the lateral surface of the mandible superiorly. This will give access to the ramus and subcondylar region of the mandible.

#### **e. Preauricular Approach**

The preauricular approach is excellent for exposure to the TMJ.<sup>47,48</sup>

- Make the incision in the preauricular fold 2.5–3.5 cm in length, as described by Thoma<sup>48</sup> and Rowe.<sup>49</sup> Take care not to extend the incision inferiorly, since it may encounter the facial nerve as it enters the posterior border of the parotid gland.
- Carry the incision and dissection along the lateral perichondrium of the tragal cartilage.
- Superiorly, if the temporal fascia is encountered, the dissection should be carried deep through the superficial temporal fascia or the temporoparietal fascia. The aid of a nerve stimulator or facial nerve monitor should be considered if the dissection approaches the orbital or frontal branch of the facial nerve.

## CHAPTER 5: Mandibular Trauma

- Make an incision through the outer layer of the temporalis fascia from the root of the zygomatic arch anterosuperiorly toward the upper corner of the retracted flap. Through this temporalis fascia incision and deep to the fascia, insert the periosteal elevator approximately 1 cm and sweep the elevator back and forth.
- Following the periosteal elevator dissection, sharply release the intervening tissue posteriorly along the plane of the initial incision, and retract this flap anteriorly, exposing the joint capsule.
- Avoid opening the joint capsule, unless it is required for fracture repair.

### **f. Facelift (Rhytidectomy) Approach**

The facelift approach provides the same exposure as the retromandibular and preauricular approaches combined. However, the skin incision is placed in a more esthetic location.

### **g. Intraoral Approach to the Condyle**

The ramus and condyle region can be exposed via an intraoral approach by extending the standard vestibular incision in a superior direction up the ascending ramus. Transoral endoscopic techniques through this incision are broadening the indications for open reduction of condylar fractures by protecting the facial nerve and offering the patient minimal facial scarring.<sup>50-53</sup>

## **3. Osteosynthesis**

Osteosynthesis is the reduction and fixation of a bone fracture with implantable devices.

### **a. Wire Osteosynthesis**

Wire osteosynthesis is used for limited definitive fixation and is helpful in alignment of fractures prior to rigid fixation. Though wire osteosynthesis is now rarely used for definitive fixation since the advent of rigid fixation,<sup>54</sup> it is useful for helping to align fractured segments prior to rigid fixation.

Wire osteosynthesis may be placed by an intraoral or extraoral route. The wire should be a prestretched soft stainless steel to reduce stretching and loosening postoperatively. The direction of the pull of the wire should be placed perpendicular to the fracture site.

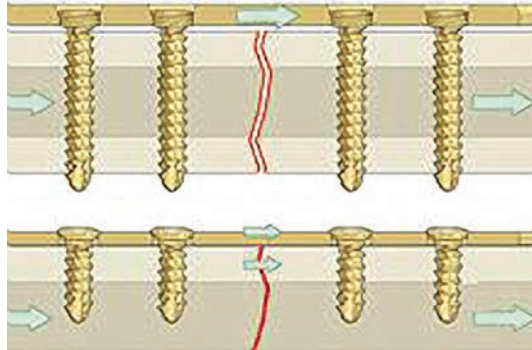
A figure-of-eight wire can produce increased strength over the straight wire when used at the inferior or superior border of the mandible.

### **b. Plate Osteosynthesis**

Plate fixation can be a “load-bearing” or “load-sharing” osteosynthesis (Figure 5.14).<sup>55</sup>

**Figure 5.14**

The upper image demonstrates a load-bearing plate used when the bone cannot bear the functional forces. In the lower image, the bone stock is sufficient to help a smaller load-sharing plate bear these forces.



#### *i. Load-Bearing Osteosynthesis*

Load-bearing osteosynthesis requires a rigid plate to bear the entire force of movement at the fracture during function. Load-bearing plates are indicated for comminuted fractures and fractures of atrophic edentulous.

#### *ii. Load-Sharing Osteosynthesis*

Load-sharing osteosynthesis creates fracture stability with shared buttressing by significant bone contact and the plate used for fixation. This requires adequate bone stock at the fracture site to create resistance to movement. Examples of load-sharing osteosynthesis include lag-screw fixation,<sup>56</sup> compression plating, and a miniplate fixation technique popularized by Champy.<sup>34</sup> Load-sharing osteosynthesis cannot be used in comminuted or atrophic edentulous fractures because of lack of bone buttressing at the site.

Ellis demonstrated that load-sharing miniplate fixation had markedly less major complications than a rigidly fixated load-bearing fixation.<sup>37,56</sup> Singh found no significant difference in incidence of complications in mandible fractures treated with the Champy miniplate technique or 3-dimensional miniplate fixation.<sup>57</sup>

## **4. Surgical Treatment**

Information about surgical treatment can be found on the AO Foundation's (Davos, Switzerland) Web site<sup>55</sup> and other sites.

## CHAPTER 5: Mandibular Trauma

### **a. Symphysis and Parasymphysis**

- Mandibular symphysis undergoes twisting (torsion) forces. Simple fractures can be treated with arch bars and 6 weeks of MMF alone.
- Wire osteosynthesis requires using 24-gauge (0.5-mm) inferior border wire and MMF.
- Plate osteosynthesis requires two straight plates or a reconstruction plate. The farther apart (superior/inferior) the plates, the more stable the fracture site.
- Reduction can be assisted by inferior border wire or monocortical screws/clamp.
- Mental nerve and tooth root injury must be avoided.

### **b. Body**

- Simple body fractures can be treated with arch bars and 6 weeks of MMF alone. They can also be treated with MMF with miniplate fixation.
- Wire osteosynthesis requires using 24-gauge (0.5-mm) superior border wire and MMF.
- Utilize multiple lag screw fixation of fractures in a sagittal plane with appropriate overlap.
- Plate osteosynthesis requires two straight plates or a reconstruction plate.
- Complex fractures and edentulous fractures require reconstruction plate fixation.

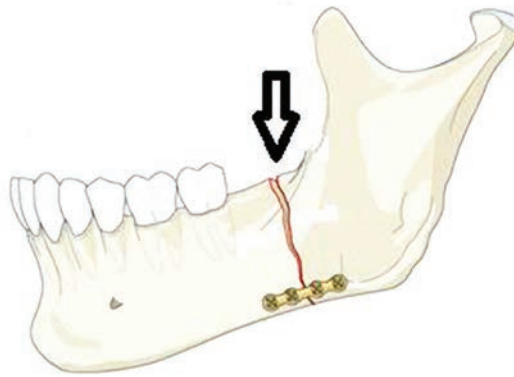
### **c. Angle**

- Simple fractures can be treated with arch bars and 6 weeks of MMF alone.
- Wire osteosynthesis requires using 24-gauge (0.5-mm) superior border wire and MMF.
- Champy showed that functional loading of a simple angle fracture creates tension (distraction) on the upper border of the fracture and is treated by a tension band. Failure to do this allows the fracture to open (Figure 5.15). In the same regard, compression occurs on the lower border during functional loading and stabilizes this portion of the fractured bone. The Champy miniplate fixation technique extends medial to lateral over the external oblique ridge. For additional stability, a second inferior border plate via transcutaneous trocar technique can be added to the Champy technique or to a superior border plate.
- Complex fractures may require reconstruction plate fixation.



**Figure 5.15**

Insufficient fixation of a mandibular fracture can result in fixation failure, infection, malocclusion, and nonunion. Lack of a tension band here allows muscle pull and occlusal forces to open the site.



**d. Condyle**

- All condylar fractures can be treated closed with MMF and/or with functional therapy using immediate function with elastics.
- Open access may be external, transoral, or transoral endoscopic-assisted ORIF. The endoscopic-assisted technique is similar in fixation, but requires a learning curve for fragment manipulation and one and two plate reduction strategies.
- Open techniques may require facial nerve protection using a facial nerve stimulator, or monitoring before induction of muscle relaxants during general anesthesia.
- Two techniques for plating are a single 2.0 mandibular plate with two screws on each side of the fracture, or two miniplates in triangular fashion, one below the sigmoid notch and one along the posterior border.
- Reduction and manipulation of the fracture are best accomplished with a mobile jaw.

**e. Additional Considerations**

*i. Locking versus Nonlocking Plates*

Tightening screws on a malformed nonlocking plate will draw the bone segments toward the plate, which may affect the occlusion. Locking plates do not do this. They also preserve cortical bone perfusion and are unlikely to loosen from the plate.

*ii. Comminuted Fractures*

Reduce the main fragments by fixing them into occlusion with MMF. Then using miniplates, realign the comminuted fragments to establish bony continuity before placing the reconstruction plate if indicated.

## CHAPTER 5: Mandibular Trauma

### *iii. External Fixator or Alternative Biphasic Pin Fixation*

External fixator or alternative biphasic pin fixation can be used for bone healing. However, neither provides the same degree of stability as reconstruction plates. Therefore, they should be considered temporary, rather than definitive.

## **VI. Prevention and Management of Complications**

### **A. INFECTION PREVENTION**

Antibiotics reduce the risk of infection when given in the preoperative period, especially in open fractures.<sup>32,33</sup> However, antibiotics may not improve infection rate in the postoperative period.<sup>58,59</sup>

Infections are generally oral flora, which are mixed infections containing streptococci and anaerobes. Treatment is surgical drainage and debridement and prolonged antibiotic therapy.

Systemic factors include alcoholism, immunocompromised patients, and poorly controlled diabetes. Local factors include poor reduction and immobilization, poorly closed oral wounds, fractured teeth in the line of fracture, diminished blood supply, devitalized tissue, and comminuted fractures.

### **B. TEETH IN LINE OF FRACTURE**

Removal of teeth in the line of fracture should be evaluated for retention first, as studies have shown that most teeth will recover function. Teeth with crown fracture and pulp exposure may be retained if emergency endodontics is planned.

Tooth removal is recommended if the tooth is luxated from its socket or interfering with fracture reduction, if the tooth or root is fractured, or if the tooth has nonrestorable caries or advanced periodontal disease or damage.

A bony impacted third molar can be retained when it stabilizes the fracture, but should be removed if partially erupted and associated with pericoronitis or follicular cyst formation.<sup>60-62</sup>

### **C. DELAYED UNION AND NONUNION**

Delayed union is a temporary condition that may progress to nonunion without adequate reduction and immobilization.

Nonunion is the failure of bone healing between the fractured segments. It is characterized by pain and abnormal mobility at the fracture site following treatment, and occurs in 3-5 percent of fractures. The most common cause of nonunion is inadequate reduction and

immobilization. Other causes include infection, inaccurate reduction, and lack of contact between fragments, traumatic ischemia, and periosteal stripping.

Alcoholism is a major contributor to both delayed union and nonunion, combined with poor compliance, poor nutrition, poor oral hygiene, and tobacco abuse.

Treatment of delayed union and nonunion includes identifying the cause, controlling infection, surgically debriding devitalized tissues, removing existing hardware, refreshing the bone at fracture ends, reestablishing correct occlusion, stabilizing segments with a 2.4 locking plate, and grafting autogenous bone.

#### **D. MALUNION**

Malunion is the improper alignment of the healed bony segments. It is caused by improper reduction, inadequate occlusal alignment during surgery, imprecise internal fixation, or inadequate stability of the fracture site.

Not all malunions are clinically significant. When teeth are involved in the malunion, a malocclusion may result.

Treatment of malunion often requires identification of the cause, and then orthodontics for small discrepancies or an open surgical approach with standard osteotomies, refracturing, or both.<sup>63</sup>

#### **E. TMJ ANKYLOSIS**

Ankylosis is a process where the mandibular condyle fuses to the glenoid fossa. It results from intra-articular hemorrhage, which leads to joint fibrosis and eventual ankylosis. Ankylosis may also cause underdevelopment due to injury of the mandibular growth center.

Ankylosis can be prevented by using shorter periods of MMF (2-3 weeks) and physiotherapy. Treatment may require additional surgery in the form of a gap arthroplasty or total alloplastic joint replacement.

#### **F. TRIGEMINAL (FIFTH) NERVE INJURY**

The fifth nerve, or inferior alveolar nerve and its branches, is the most commonly injured nerve in mandibular fracture. The deficit is numbness or other sensory changes in the lower lip and chin. Most of the sensory and motor functions of these nerves improve and return to normal with time. Iatrogenic injury must be avoided when treating fifth nerve injury.

#### **G. FACIAL (SEVENTH) NERVE INJURY**

Seventh nerve assessment in the severely traumatized patient may be difficult if the patient is obtunded and facial nerve testing is limited to

## CHAPTER 5: Mandibular Trauma

observing grimacing with painful stimulation. The nerve can be injured anywhere throughout its course.

Three major areas of concern for facial nerve injury is to the main trunk in the region of the condylar neck, marginal mandibular nerve injury in the submandibular approach, and frontal branch injury in the preauricular approach to the condyle.

Facial nerve monitoring should be considered on open approaches to avoid further injury.

### H. FIXATION FAILURE

Fixation failure results in fracture mobility that can lead to nonunion, malunion, or infection. Causes include insufficient fixation, fracture of the plate, loosening of the screws, and devitalization of the bone around the screws (Figure 5.15).

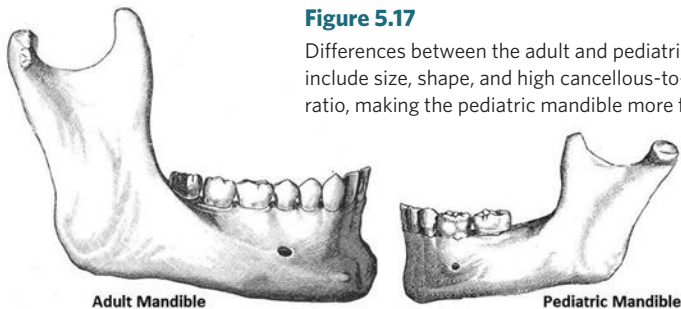
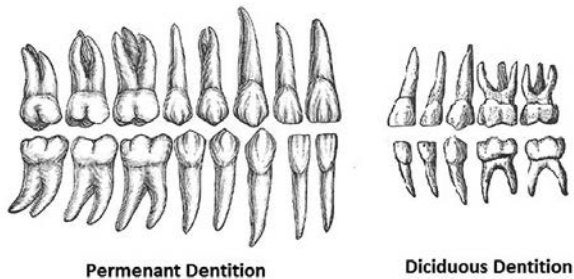
## VII. Pediatric Mandibular Fractures

### A. PEDIATRIC DENTAL AND SKELETAL ANATOMY

The dentition (Figure 5.16) and mandible (Figure 5.17) in children are very different from those in adults. Pediatric teeth have poor retentive

**Figure 5.16**

Differences in crown and root structure between permanent and deciduous teeth.



**Figure 5.17**

Differences between the adult and pediatric mandible include size, shape, and high cancellous-to-cortical ratio, making the pediatric mandible more flexible.

qualities, the roots are short and narrow, and the crowns have reduced retention contours, making them poor candidates for circumdental wire fixation. The pediatric mandible fracture patterns are due to mixed dentition developing permanent tooth buds, and to high greenstick pathologic fractures due to the high cancellous-to-cortical-bone ratio, giving the pediatric mandible more elasticity.<sup>64-66</sup>

A child's condyle is the growth center for the mandible. Thus, trauma or iatrogenic injury may cause growth retardation, malocclusion, and facial asymmetry.

## **B. FREQUENCY OF PEDIATRIC MANDIBULAR FRACTURES**

Although less frequent than in adults and second to nasal fractures, mandibular fractures are the most common facial fracture reported in hospitalized pediatric trauma patients.<sup>67-70</sup> The impact is usually absorbed by the large skull.

Children ages 6-15 have a higher percentage of luxation, avulsion, fractures, and dislocations. Mandibular fractures are rare in children under 5 years. MacLennan has shown under 6 years at 1 percent,<sup>67</sup> children aged 6-11 at 5 percent,<sup>68</sup> and under 16 years 7.7 percent.<sup>69</sup>

The distribution between the sexes is similar to a 2:1 male predominance for all mandibular fractures and an 8:1 predominance for condylar fractures.

## **C. MANAGEMENT OF PEDIATRIC MANDIBULAR FRACTURES**

Closed reduction is recommended for mandibular fractures to prevent damage to the developing permanent dentition.<sup>71</sup> Dental impressions and dental model surgery may be necessary to build a lingual splint to reduce and immobilize pediatric mandibular fractures. If wire osteosynthesis is required, it should be limited to the inferior border of the mandible.

Condyle fractures in children are best managed by closed reduction to avoid joint injury and growth retardation sequella.<sup>72</sup> Early physiotherapy in 7-10 days will avoid restriction of joint movement.<sup>73</sup>

### **1. Imaging Pediatric Mandibular Fractures**

#### **a. Mandibular Series**

- *Lateral oblique*—View from the condyle to the mental foramen.
- *Posteroanterior (PA)*—View of the ramus, angle, and body.
- *Reverse Towne (PA)*—Medial/lateral displacement of condylar fractures. Better than Panorex in acute care setting.

## CHAPTER 5: Mandibular Trauma

### **b. Panorex**

Panorex is difficult in the critically injured and uncooperative. It is the study of choice for mandible fractures.

### **c. CT Scanning**

CT scanning provides a thin cut with three-dimensional and multiplanar reconstructions. It is especially useful for TMJ evaluation.

### **d. Occlusal Views**

Occlusal views are used for evaluating symphyseal displacement.

### **e. Periapical Radiographs**

Periapical radiographs are used for evaluating root and alveolar fractures.

## **2. Treating Pediatric Mandibular Fractures**

The general management principles for treating pediatric mandibular fractures are similar to those for adults, but differ because of the mixed dentition. Restoration of occlusion, function, and facial balance is required for successful treatment. The developmental growth of the child's face must be taken into consideration.<sup>74-77</sup> Proper treatment may prevent complications, such as growth disturbance and infection.

- *Younger than 2 years*—Before age 2, a child's jaws are often edentulous. Mandibular fracture would require an acrylic splint fixed with circummandibular wires. If immobilization of the jaw is necessary, the splint may be fixed to both occlusive surfaces, with both circummandibular wires and wires through the pyriform aperture.<sup>78,79</sup>
- *6-12 years*—At ages 2-5 years, deciduous teeth are present and conical in shape (Figure 5.17). Interdental wiring may be used for fixation. Arch bars are difficult to secure below the gum line, and may require resin to attach wire for fixation.
- *6-12 years*—In this age group, the mixed dentition, primary teeth are resorbing and often are loose. In children 5-8 years, deciduous molars may be used for fixation, and in children 7-11 years, the primary molars and incisors may be used for fixation. When dentition is not available, splints may be used.
- *9-12 years*—In this age group, MMF using arch bars is possible, because enough permanent dentition is present.

Healing in children is rapid and often requires 10-20 days of immobilization. Delay in treatment may require callus removal for proper reduction. When ORIF is necessary the use of monocortical screws should be considered at the inferior mandibular border to prevent damage to developing permanent dentition. Resorbable polylactic and

polyglycolic acid plates and screws may reduce the long-term implant related complications.<sup>44,80-82</sup>

### 3. Treating Pediatric Condylar Fractures

Pediatric condylar fractures are rare, occurring in 6 percent of children younger than 15 years.<sup>81</sup>

Condylar fractures are classified into three groups: (1) Intracapsular (articular cartilage) condylar fractures; (2) high condylar fractures, which occur above the sigmoid notch; and (3) low subcondylar fractures, which usually are greenstick fractures in children and are the most common type of pediatric mandibular fracture overall.

- *Younger than 3 years*—In children younger than 3 years, the condylar neck is short and thick (Figure 5.17). Traumatic forces generally concentrate on the articular cartilage. Injuries to the articular cartilage may cause hemarthrosis, subsequent bony ankylosis, and affects mandibular growth. Early range of motion is important in preventing this complication.
- *Younger than 5 years*—In children younger than 5 years, crush injuries to the articular disk are more common.
- *Over 5 years*—In children over 5 years, simple neck fractures are more common. Most are treated nonoperatively with early treatment, including analgesics, soft diet, and progressive range-of-motion exercise.

#### **a. Immobilization in MMF**

Comminuted and displaced fractures of the head and condyle are immobilized in MMF for 2 weeks. Bilateral fractures causing open bite, severe movement limitation, or deviation are immobilized in MMF for 2-3 weeks. This is followed by 6-8 weeks of guiding elastics to counteract posterior ptergomasseteric muscle sling pull that shortens the posterior mandible and opens the bite anteriorly.

#### **b. Open Reduction**

With similar indications as adults, open reduction is indicated for (1) dislocation of the mandibular condyle into the middle cranial fossa, (2) condylar fractures prohibiting mandibular movement, and (3) in some cases, bilateral condylar fractures causing reduced ramus height and anterior open bite. However, for most bilateral condylar fractures, immobilization only is recommended. Depending on the fracture site, the open surgical approach to the pediatric condyle is similar to that of the adult condyle.

## CHAPTER 5: Mandibular Trauma

### 4. Treating Pediatric Body and Angle Fractures

- Greenstick fractures are managed with soft diet and pain control.
- Minimal to moderate displacement is treated with MMF with or without elastics.
- Angle fractures cannot be treated with dental splints.
- An extraoral open reduction approach may be indicated for severe displacement.

### 5. Treating Pediatric Dentoalveolar Fractures

Dentoalveolar injuries range from 8 percent to 50 percent of pediatric mandibular fractures.

#### a. Primary Teeth

Replacement of primary teeth is unnecessary. Primary teeth act as space holders for the permanent dentition. Space-holding appliances may be needed after the premature loss of primary teeth in trauma.

#### b. Permanent Teeth

- Permanent teeth should be reinserted within 2 hours. The teeth may be transported in saline or milk.
- Single or multiple teeth may be fixated with wire-acid etch composite splinting using stainless steel wire. Care should be taken to avoid the gingiva and the opposing teeth (Figure 5.12).
- The fractured segment may be reduced, and the patient is placed in MMF.
- Large fractured segments may require plate-screw fixation, if this is possible without injuring the teeth.

## VIII. References

1. Peltier J, Ryan MW. Mandible fractures. Grand Rounds Presentation. Galveston, Texas: University of Texas Medical Branch, Department of Otolaryngology; May 26, 2004. Accessed at: <http://www.utmb.edu/otoref/grnds/Mandible-fx-040526/Mandible-fx-040526.htm>.
2. Barton JR. A systemic bandage for fractures of the lower jaw. *Am Med Recorder Phila.* 1819;2:153.
3. Gunning TB. Treatment of fracture of the lower jaw by interdental splints, I. *Amer J Dent Sci.* 1868;2:53-55.
4. Gilmer TL. A case of fracture of the lower jaw with remarks on treatment. *Arch Dent.* 1887;43(4):388.



5. Erich JB, Austin LT. *Traumatic Injuries of the Facial Bones: An Atlas of Treatment*. Philadelphia, PA: WB Saunders Co; 1944:203 ff.
6. Gilardino MS, Chen E, Bartlett SP. Choice of internal rigid fixation materials in the treatment of facial fractures. *Craniomaxillofac Trauma Reconstr*. 2009;2(1):49-60.
7. Moon H. Mechanical appliances for treatment of fracture of the jaws. *Br J Dent Sci*. 1874; 17:303.
8. Spiessl B. Rigid internal fixation of fractures of the lower jaw. *Reconstr Surg Traumatol*. 1972;13:124-40.
9. MacLennan WD. Consideration of 180 cases of typical fractures of the mandibular condylar process. *Br J Plast Surg*. 1952;5:122-128.
10. Lindahl L. Condylar fractures of the mandible; I. Classification and relation to age, occlusion, and concomitant injuries of the teeth and teeth-supporting structures, and fractures of the mandibular body. *Intl J Oral Surg*. 1978;6(1):12-21.
11. Bradley PF. Injuries of the condylar and coronoid processes. In: Rowe NL, Williams JL, eds. *Maxillofacial Injuries*. Edinburgh, Scotland: Churchill Livingstone; 1985:337-362.
12. Luc MH, Smets PA, Van Damme PJ, Stoelinga W. Non-surgical treatment of condylar fractures in adults: A retrospective analysis. *Journal of Cranio-Maxillofacial Surgery*. June 2003;31(3):162-167.
13. Spiessl B, Schroll K. Gesichtsschadl. In: Nigst H, ed. *Spezielle Fracturen- und Luxationslehre*. Vol. I, Ch. 1. Stuttgart, Germany: Thieme; 1972.
14. Krenkel C. Treatment of mandibular condylar fractures. *Atlas Oral Maxillofac Surg Clin North Am*. 1997;5(1):127-155.
15. Neff A, Mühlberger G, Karoglan M, et al. Stability of osteosyntheses for condylar head fractures in the clinic and biomechanical simulation. *Mund Kiefer Gesichtschir*. 2004;8(2):63-74 [German].
16. Ellis E 3rd, Moos KF, el-Attar A. Ten years of mandibular fractures: An analysis of 2,137 cases. *Oral Surg Oral Med Oral Pathol*. Feb 1985;59(2):120-129.
17. Zide MF, Kent JN. Indications for open reduction of mandibular condyle fractures. *J Oral Maxillofac Surg*. Feb 1983;41(2):89-98.

## CHAPTER 5: Mandibular Trauma

18. Palmieri C, Ellis E 3rd, Throckmorton G. Mandibular motion after closed and open treatment of unilateral mandibular condylar process fractures. *J Oral Maxillofac Surg.* Jul 1999;57(7):764-75; discussion 775-776.
19. De Riu G, Gamba U, Anghinoni M, Sesenna E. A comparison of open and closed treatment of condylar fractures: A change in philosophy. *Int J Oral Maxillofac Surg.* Oct 2001;30(5):384-389.
20. Olson RA, Fonseca RJ, Zeitler DL, Osbon DB. Fractures of the mandible: A review of 580 cases. *J Oral Maxillofac Surg.* Jan 1982;40(1):23-28.
21. Ellis E 3rd, Price C. Treatment protocol for fractures of the atrophic mandible. *J Oral Maxillofac Surg.* Mar 2008;66(3):421-435.
22. Gruenbaum, Tamar. Famous figures in dentistry mouth. *JASDA.* 2010;30(1):18.
23. Schneider M, Erasmus F, Gerlach KL, Kuhlisch E, Loukota RA, Rasse M. Open reduction and internal fixation versus closed treatment and mandibulomaxillary fixation of fractures of the mandibular condylar process: A randomized, prospective, multicenter study with special evaluation of fracture level. *J Oral Maxillofac Surg.* Dec 2008;66(12):2537-2544.
24. Sorel B. Open versus closed reduction of mandible fractures. *Oral and Maxillofacial Surgery Clinics of North America.* 1998;10:553.
25. Manson PN. Facial fractures. Chapter 66 in: Mathes SJ. *Plastic Surgery.* Vol. 3. 2nd ed. Philadelphia, PA: Saunders Elsevier; 2006:77-380.
26. Schmidt BL, Kearns G, Gordon N, Kaban LB. A financial analysis of maxillomandibular fixation versus rigid internal fixation for treatment of mandibular fractures. *J Oral Maxillofac Surg.* Nov 2000;58(11):1206-1210; discussion 1210-1.
27. Shetty V, Atchison K, Leathers R, Black E, Zigler C, Belin TR. Do the benefits of rigid internal fixation of mandible fractures justify the added costs? Results from a randomized controlled trial. *J Oral Maxillofac Surg.* Nov 2008;66(11):2203-2212.
28. Marshall MD, Buchbinder D. Pediatric mandibular injury. *Facial Plast Surg.* May 1999;7(2):195-203.

29. Valiati R, Ibrahim D, Abreu ME, Heitz C, de Oliveira RB, Pagnoncelli RM. The treatment of condylar fractures: To open or not to open? A critical review of this controversy. *Int J Med Sci.* 2008;5(6):313-318.
30. Baker S, Betts NJ. Mandibular angle fractures. *Oral and Maxillofacial Surgery Knowledge Update.* 1998;2:25.
31. Ellis E 3rd, Palmieri C, Throckmorton G. Further displacement of condylar process fractures after closed treatment. *J Oral Maxillofac Surg.* Nov 1999;57(11):1307-1316; discussion 1316-7.
32. Zallen RD, Curry JT. A study of antibiotic usage in compound mandibular fractures. *J Oral Surg.* Jun 1975;33(6):431-434.
33. James RB, Fredrickson C, Kent JN. Prospective study of mandibular fractures. *J Oral Surg.* Apr 1981;39(4):275-281.
34. Champy M, Loddé JP, Schmitt R, Jaeger JH, Muster D. Mandibular osteosynthesis by miniature screwed plates via a buccal approach. *J Maxillofac Surg.* Feb 1978;6(1):14-21.
35. Smith WP. Delayed miniplate osteosynthesis for mandibular fractures. *Br J Oral Maxillofac Surg.* Apr 1991;29(2):73-76.
36. Tuovinen V, Nørholt SE, Sindet-Pedersen S, Jensen J. A retrospective analysis of 279 patients with isolated mandibular fractures treated with titanium miniplates. *J Oral Maxillofac Surg.* Sep 1994;52(9):931-935; discussion 935-6.
37. Ellis E 3rd. Treatment methods for fractures of the mandibular angle. *J Craniomaxillofac Trauma.* Spring 1996;2(1):28-36.
38. Biller JA, Pletcher SD, Goldberg AN, Murr AH. Complications and the time to repair of mandible fractures. *Laryngoscope.* May 2005;115(5):769-772.
39. Webb LS, Makhijani S, Khanna M, Burstein MJ, Falk AN, Koumanis DJ. A comparison of outcomes between immediate and delayed repair of mandibular fractures. *Can J Plast Surg.* 2009;17(4):124-126.
40. Barker DA, Oo KK, Allak A, Park SS. Timing for repair of mandible fractures. *Laryngoscope.* Jun 2011;121(6):1160-1163.
41. Risdon F. Ankylosis of the temporomandibular joint. *J Am Dent Assoc.* 1934;21:1933.
42. Ellis 3rd E, Zide MF. Transfacial approaches to the mandible. Section 5 in: Ellis 3rd E, Zide MF. *Surgical Approaches to the Facial Skeleton.* 2nd ed. Philadelphia, PA: Lippincott Williams & Wilkins; 2005:151-189.

## CHAPTER 5: Mandibular Trauma

43. Dingman RO, Grabb WC. Surgical anatomy of the mandibular ramus of the facial nerve based on the dissection of 100 facial halves. *Plast Reconstr Surg Transplant Bull.* Mar 1962;29:266-272.
44. Khatri A, Kalra N. A conservative approach to pediatric mandibular fracture management: Outcome and advantages. *Indian J Dent Res.* Nov 2011;22(6):873-876.
45. Hinds EC. Correction of prognathism by subcondylar osteotomy. *J Oral Surg (Chic).* May 1958;16(3):209-214.
46. Hinds EC, Girotti WJ. Vertical subcondylar osteotomy: A reappraisal. *Oral Surg Oral Med Oral Pathol.* Aug 1967;24(2):164-170.
47. Kempers KG, Quinn PD, Silverstein K. Surgical approaches to mandibular condylar fractures: A review. *J Craniomaxillofac Trauma.* Winter 1999;5(4):25-30.
48. Thoma KH. Treatment of condylar fractures. *J Oral Surg (Chic).* Apr 1954;12(2):112-120.
49. Rowe NL. Surgery of the temporomandibular joint. *Proc R Soc Med.* Apr 1972;65(4):383-388.
50. Chen CT, Lai JP, Tung TC, Chen YR. Endoscopically assisted mandibular subcondylar fracture repair. *Plast Reconstr Surg.* Jan 1999;103(1):60-65.
51. Lee C, Forrest CR. Endoscopic facial fracture management: Techniques. Chapter 68 in: Mathes SJ. *Plastic Surgery.* Vol. 3. 2nd ed. Philadelphia, PA: Saunders Elsevier; 2006:463-4579.
52. Martin M, Lee C. Endoscopic mandibular condyle fracture repair. *Atlas Oral Maxillofac Surg Clin North Am.* Sep 2003;11(2):169-178.
53. Kellman RM, Cienfuegos R. Endoscopic approaches to subcondylar fractures of the mandible. *Facial Plast Surg.* Feb 2009;25(1):23-28.
54. Theriot BA, Van Sickels JE, Triplett RG, Nishioka GJ. Intraosseous wire fixation versus rigid osseous fixation of mandibular fractures: A preliminary report. *J Oral Maxillofac Surg.* Jul 1987;45(7):577-582.
55. Buchbinder D, Ellis E, Figari M, Sánchez G, Aniceto G, Shimoizato K, eds. *CMF Surgery Reference.* AO Foundation. Accessed 7/12/12 at: <https://www2.aofoundation.org/wps/portal/surgery?showPage=diagnosis&bone=CMF&segment=Overview&showCMF=true>.

56. Ellis E 3rd. Management of fractures through the angle of the mandible. *Oral Maxillofac Surg Clin North Am.* May 2009;21(2):163-174.
57. Ellis 3rd E, Zide MF. Transoral approaches to the facial skeleton. Section 4 in: Ellis 3rd E, Zide MF. *Surgical Approaches to the Facial Skeleton*. 2nd ed. Philadelphia, PA: Lippincott Williams & Wilkins; 2005:109-150.
58. Abubaker AO, Rollert MK. Postoperative antibiotic prophylaxis in mandibular fractures: A preliminary randomized, double-blind, and placebo-controlled clinical study. *J Oral Maxillofac Surg.* Dec 2001;59(12):1415-1419.
59. Miles BA, Potter JK, Ellis E 3rd. The efficacy of postoperative antibiotic regimens in the open treatment of mandibular fractures: A prospective randomized trial. *J Oral Maxillofac Surg.* Apr 2006;64(4):576-582.
60. Neal DC, Wagner WF, Alpert B. Morbidity associated with teeth in the line of mandibular fractures. *J Oral Surg.* Nov 1978;36(11):859-862.
61. de Amaratunga NA. The effect of teeth in the line of mandibular fractures on healing. *J Oral Maxillofac Surg.* Apr 1987;45(4):312-314.
62. Shetty V, Freymiller E. Teeth in the line of fracture: A review. *J Oral Maxillofac Surg.* Dec 1989;47(12):1303-1306.
63. Moore GF, Olson TS, Yonkers AJ. Complications of mandibular fractures: A retrospective review of 100 fractures in 56 patients. *Nebr Med J.* Apr 1985;70(4):120-123.
64. Tanaka N, Uchide N, Suzuki K. Maxillofacial fractures in children. *J Craniomaxillofac Surg.* Oct 1993;21(7):289-293.
65. Martins C. Prognosis of mandibular fracture in pediatric population. *Int Congr Ser.* 2003;1254:473-475
66. Lida S, Matsuya T. Pediatric maxillofacial fractures: Their etiological characters and fracture patterns. *J Cranio Maxillofac Surg.* 2002;30:237-241.
67. MacLennan WD. Fractures of the mandible in children under the age of six years. *Br J Plast Surg.* 1956;9:125.

## CHAPTER 5: Mandibular Trauma

68. Rowe NL. Fractures of the jaws in children. *J Oral Surg.* Jul 1969;27(7):497-507.
69. Thoren H, Iizuka T, Hallikainen D. Different patterns of mandibular fractures in children. An analysis of 220 fractures in 157 patients. *J Craniomaxillofac Surg.* Oct 1992;20(7):292-296.
70. Kaban LB. Facial trauma I. Midface fracture. In: Kaban LB, ed. *Pediatric Oral and Maxillofacial Surgery*. 2nd ed. Philadelphia, PA: WB Saunders Co.; 1990:210-212.
71. Marshall MD, Buchbinder D. Pediatric mandibular injury. *Facial Plast Surg.* May 1999;7(2):195-203.
72. Ferreira PC, Amarante JM, Silva PN, et al. Retrospective study of 1251 maxillofacial fractures in children and adolescents. *Plast Reconstr Surg.* May 2005;115(6):1500-1508.
73. Güven O, Keskin A. Remodelling following condylar fractures in children. *J Craniomaxillofac Surg.* Aug 2001;29(4):232-237.
74. Kaban LB, Mulliken JB, Murray JE. Facial fractures in children: An analysis of 122 fractures in 109 patients. *Plast Reconstr Surg.* Jan 1977;59(1):15-20.
75. Posnick JC, Wells M, Pron GE. Pediatric facial fractures: Evolving patterns of treatment. *J Oral Maxillofac Surg.* Aug 1993;51(8):836-844; discussion 844-845.
76. Myall RW. Management of mandibular fractures in children. *Oral Maxillofac Surg Clin North Am.* May 2009;21(2):197-201, vi.
77. Cole P, Kaufman Y, Izaddoost S, Hatfeg DA, Hollier L. Principles of pediatric mandibular fracture management. *Plast Reconstr Surg.* Mar 2009;123(3):1022-1024.
78. Kushner GM, Tiwana PS. Fractures of the growing mandible. *Atlas Oral Maxillofac Surg Clin North Am.* Mar 2009;17(1):81-91.
79. Goth S, Sawatari Y, Peleg M. Management of pediatric mandible fractures. *J Craniofac Surg.* Jan 2012;23(1):47-56.
80. Hegab A. Management of mandibular fractures in children with a split acrylic splint: A case series. *Br J Oral Maxillofac Surg.* Dec 5 2011.

81. Eppley BL. Use of resorbable plates and screws in pediatric facial fractures. *J Oral Maxillofac Surg.* Mar 2005;63(3):385-391.
82. Poore MC, Penna KJ. The use of resorbable hardware for fixation of pediatric mandible fracture. Case report. *N Y State Dent J.* Jun-Jul 2008;74(4):58-61.

The American Academy of Otolaryngology—Head and Neck Surgery Foundation’s education initiatives are aimed at increasing the quality of patient outcomes through knowledgeable, competent, and professional physicians. The goals of education are to provide activities and services for practicing otolaryngologists, physicians-in-training, and non-otolaryngologist health professionals.

The Foundation’s AcademyU® serves as the primary resource for otolaryngology-head and neck activities and events. These include an online library of expert-developed learning courses, learning platforms, and e-books, as well as Patient Management Perspectives in Otolaryngology and the Home Study Course. In addition, the AAO-HNSF Annual Meeting & OTO EXPO is the world’s largest gathering of otolaryngologists, offering a variety of education seminars, courses, and posters. Many of the Foundation’s activities are available for *AMA PRA Category 1 Credit*™.

Visit the Academy’s Web site, [www.entnet.org](http://www.entnet.org), to find out how AcademyU® can assist you and your practice through quality professional development opportunities.





AMERICAN ACADEMY OF  
OTOLARYNGOLOGY—  
HEAD AND NECK SURGERY

F O U N D A T I O N

**American Academy of Otolaryngology—Head and Neck  
Surgery Foundation**

**1650 Diagonal Road  
Alexandria, VA 22314-2857 USA**

**T / 1.703.836.4444**

**F / 1.703.683.5100**

**[www.entnet.org](http://www.entnet.org)**